

Iatrogenic perforation of the left heart during placement of a chest drain

Jan Peter Goltz, Armin Gorski, Jürgen Böhler, Ralph Kickuth, Dietbert Hahn, Christian Oliver Ritter

ABSTRACT

Chest drain placement is a standard procedure for treating pneumothorax and pleural effusions and has a low complication rate. It is a safe and efficient procedure if image guidance is used. If the anatomic orientation is hampered and neither air nor fluids can be initially aspirated, more complex imaging than a chest x-ray is indicated to avoid major complications. We report the case of an 88-year-old male patient suffering from chronic heart failure who was admitted to another hospital following acute cardiac decompensation. Because of dyspnea with voluminous bilateral effusions, an attempt was made to drain the left pleural cavity. A malposition of the chest drain was suspected because blood was initially draining from the catheter. The hemodynamically stable patient was referred to our university hospital, where computed tomography of the chest revealed the location of the intercostal drain. The drain had perforated the left ventricle, run through the mitral valve and exited the left atrium via a pulmonary vein, ending in the middle lobe. The patient was brought to the surgical theater, where cardiac surgeons performed a left anterolateral thoracotomy and extracted the drain successfully. Three days later, the patient was discharged from our hospital in a good general condition.

Key words: • heart • chest tube • complication

Chest drain insertion is a widely used invasive therapy for treating pneumothorax and pleural effusions. The complication rate is low, especially if image guidance is used. Reported complications include infection, vascular lesion with bleeding, and injury to the lung, liver, diaphragm, stomach and spleen. We report on the very rare complication of left heart perforation after chest drain placement.

Case report

An 88-year-old male patient suffering from chronic heart failure was admitted to another hospital following acute cardiac decompensation. Because of dyspnea with voluminous bilateral effusions (left more than right), the patient was treated in the intensive care unit. The patient's medical history revealed chronic ischemic heart disease, peripheral artery disease (Fontaine IIb), hypertension and diabetes. Laboratory results were abnormal for hemoglobin (11 g/dL; normal, 14–18 g/dL) and creatinine (1.5 mg/dL; normal, <1.17 mg/dL). The other standard laboratory results were normal. Because of the patient's respiratory symptoms, including shortness of breath and an arterial oxygen saturation of 87%, in addition to a pharmacologic treatment an attempt was made to drain the left pleural cavity. No image guidance was used and the patient was half sitting up with his arm behind his head. After local anesthesia and under sterile conditions, an incision was made and an 8F-pleural catheter (Braun Pleuracan®, Melsungen, Germany) was introduced into the 5th left intercostal space in the anterior axillary line. During insertion of the drain, slight resistance was noticed at a depth of 2–3 cm. This was interpreted as adhesions and the catheter was advanced further. Immediately after insertion, blood was draining in a non-pulsatile way from the catheter so the catheter was clamped. Transthoracic ultrasound and echocardiography were performed. The imaging showed a misplaced catheter that was located within the heart.

Because of these findings, and because the patient remained hemodynamically stable, he was referred to the emergency department of our university hospital where he arrived two hours after the procedure for further evaluation. During an initial clinical evaluation the patient was found to be responsive and hemodynamically stable with a blood pressure of 145/90 mmHg and a heart rate of 89/s. After this quick clinical evaluation, contrast-enhanced computed tomography (CT) of the chest was performed (Fig. 1) with the following findings: the intercostal drain had been inserted anterolaterally into the fifth intercostal space on the left; after an intrapulmonary distance of 10 mm, the drain perforated the anterolateral wall of the hypertrophic left ventricle, leaving the ventricle through the mitral valve; from here it passed through the left atrium, exiting via a pulmonary vein. The tip of the drain was located in the contralateral lung (segment 4, middle lobe).

From the Institute of Radiology (J.P.G. ✉ goltz@roentgen.uni-wuerzburg.de, R.K., D.H., C.O.R.), and the Department of Thoracic and Cardiovascular Surgery (A.G., J.B.), University of Würzburg, Würzburg, Germany.

Received 26 November 2009; accepted 27 April 2010.

Published online 3 August 2010
DOI 10.4261/1305-3825.DIR.3131-09.0

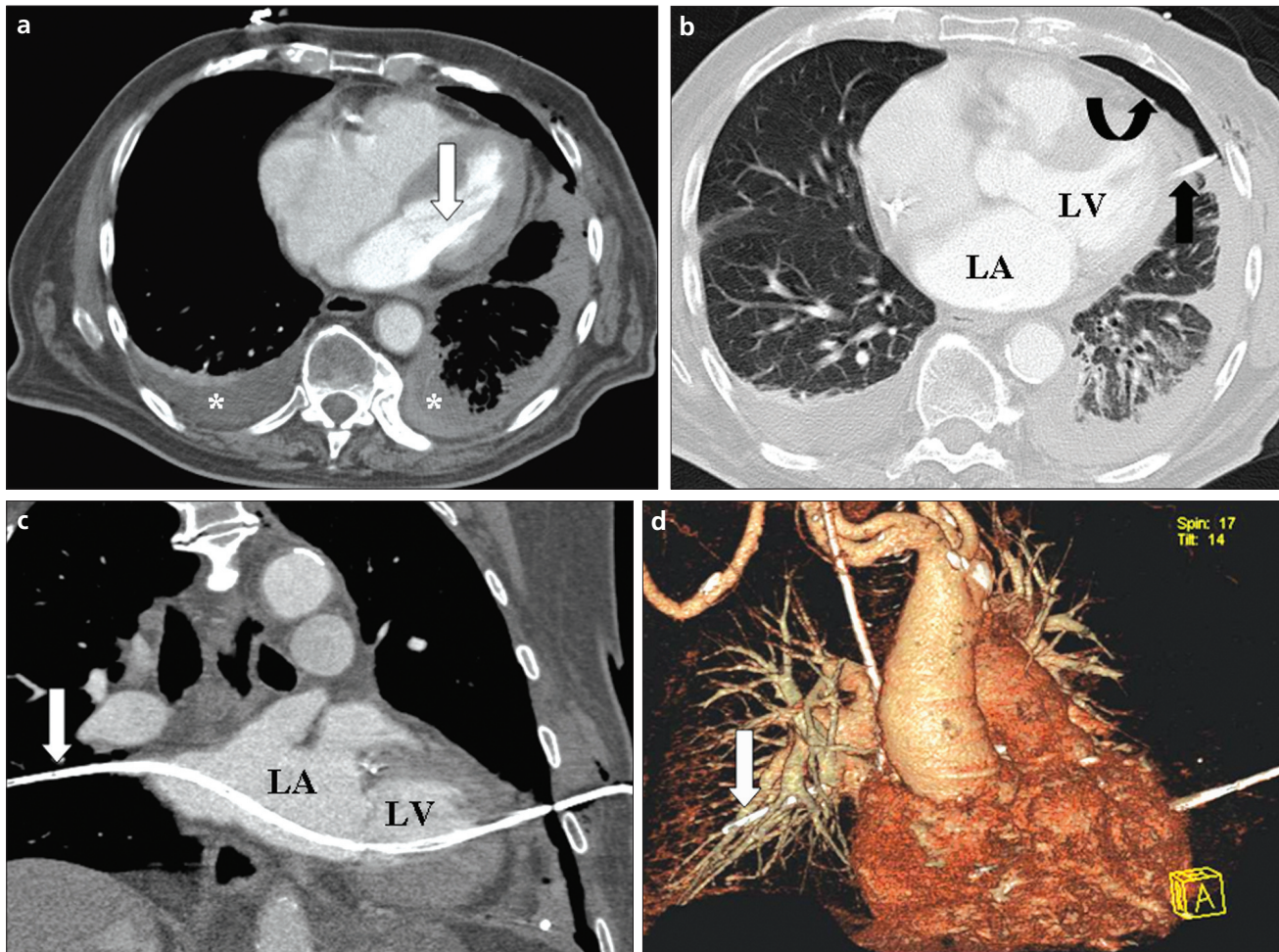


Figure 1. a–d. Mediastinal window axial CT (a) with the pleural drainage (white arrow) passing through the mitral valve; there are bilateral pleural effusions (asterisks). Lung window axial CT (b) with a small pneumothorax (curved arrow) and the drain penetrating the myocardium of the left ventricle (LV). Curved multiplanar CT reconstruction (c) along the pleural drain (white arrow) highlights the course of the drain through the left ventricle and atrium (LA) and the tip placed in the middle lobe. Oblique coronal volume-rendering 3D reconstruction (d) showing the entry and exit of the drain (arrow).

The patient was brought to the surgical theater where cardiac surgeons performed a left anterolateral thoracotomy under general anesthesia (Fig. 2). The drain was carefully extracted and both the myocardium of the left ventricle and the pericardium were sutured. During the postoperative course neither the x-ray of the chest nor an echocardiograph revealed hemothorax or pericardial tamponade. Three days later, the patient was discharged from our hospital in a good general condition.

Discussion

Chest drain placement is a standard procedure for treating pneumothorax, empyema or pleural effusion (1). The overall complication rate of chest drain placement is reported to be as high as 30%, although the major complication

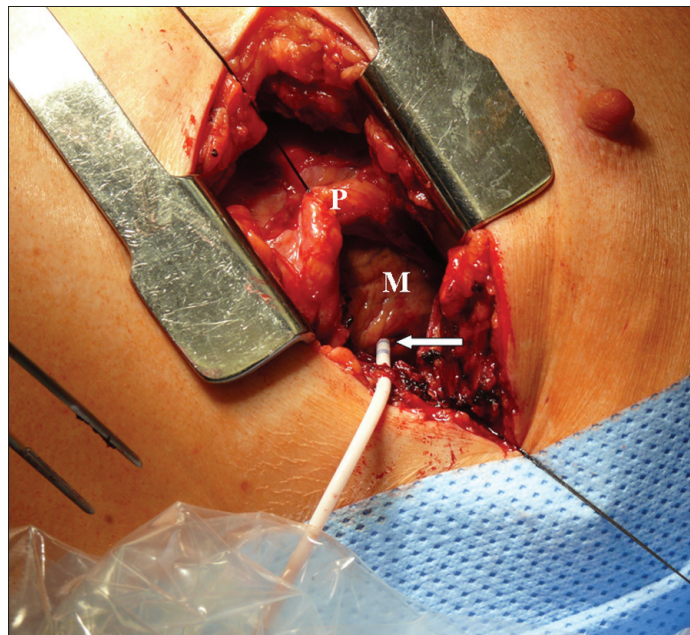


Figure 2. Intraoperative view of the left anterolateral thoracotomy with opened pericardium (P) and the 2.7 mm pleural drain (white arrow) penetrating the myocardium (M) of the left ventricle.

rate is low if the procedure is carried out properly. Major complications include laceration of the lung, liver, diaphragm, stomach, spleen, smaller blood vessels and nerves (2). One publication reported the laceration of the left subclavian vein after chest drain placement (1). A heart perforation during chest drain placement is a very rare complication that, to our knowledge, has been described in only seven publications to date. The first incidence was reported in 1986; during chest drain placement, the right ventricle was perforated due to adhesion of the pericardium to the chest wall, and the patient died shortly after insertion (3). Meisel et al. (4) reported a fatal laceration of the right atrium in a kyphoscoliotic patient. One patient survived the perforation of an enlarged right atrium (5). A perforation of the right ventricle occurred during chest drain placement in a trauma patient who did not survive (6). Another fatal perforation, in this case of the right ventricle adherent to the chest wall, was reported in a post-pneumectomy patient (7). In another case, a lethal perforation of the left ventricle was observed after chest drain placement for pneumothorax (8). The last report about a heart perforation during chest drain insertion was in 2007; due to mitral valve regurgitation, there was an accidental perforation of the massively dilated left atrium during chest drain placement for pleural effusion from the right side. That patient survived (2). Our case report describes the very rare complication of heart perforation during chest drain placement due to a dilated left ventricle that was adherent to the left-side chest wall. This is the first report of a patient in which a chest drain perforated the left ventricle and passed the mitral valve and the left atrium, with the tip ending in the pulmonary vein of the middle lobe. Only two of the seven already-published heart perforations resulted in survival of the patient as in our case.

This report emphasizes the fact that the site of drain insertion must be confirmed prior to the procedure. If anatomic orientation is hampered because of massive pleural effusion, as in this case, it is vital to aspirate air (in the case of pneumothorax) or fluid (in the case of pleural effusion) at the time of anesthesia. If this aspiration fails, the procedure should not be continued unless more complex imaging than a chest X-ray has been performed, as outlined in current guidelines for chest drain placement (9). We feel that the safest way to place a small-sized chest drain correctly is by using image guidance by ultrasound or computed tomography; however, the latter is too expensive and limited for everyday use, especially in intensive care patients. As most intensive care units currently provide ultrasound, this technique should be used for guidance as a standard. The reported complication could have potentially been avoided if imaging had been used during or prior to the procedure described. An already published study reported no procedure-related major complications when using ultrasound or computed tomography for chest drain placement (10). When placing smaller chest drains (<14F) some authors recommend Seldingers' technique or image guidance to minimize the risk of fatal complications whenever possible (1). For medium (16–24F) or large (>24F) chest drains, blunt preparation and digital palpation of the pleural space with a finger is mandatory (2). If unusual resistance is discovered during drain insertion no substantial force should be applied. The most common site of chest drain insertion is the so-called "safe triangle" which is bordered by a horizontal line through the nipples and a horizontal line through the apex below the axilla, the anterior border of the musculus latissimus dorsi and the lateral margin of the musculus pectoralis major (9).

If, despite all precautions, the heart is perforated, the drain must be clamped

and computed tomography of the chest should be performed immediately as long as the patient is in a stable hemodynamic condition. A (mini-) thoracotomy is the treatment of choice in this type of complication.

In conclusion, chest drain placement is a safe and efficient procedure for treatment of pneumothorax, empyema and pleural effusions if image guidance is used. If the anatomic orientation is difficult and neither air nor fluids can be initially aspirated, more complex imaging than a chest x-ray is indicated to avoid major complications.

References

1. Schley M, Rössler M, Konrad CJ, et al. Damage of the subclavian vein with a thorax drainage. *Anaesthesist* 2009; 58:387–390.
2. Kerger H, Blaettner T, Froehlich C, et al. Perforation of the left atrium by a chest tube in a patient with cardiomegaly: management of a rare, but life-threatening complication. *Resuscitation* 2007; 74:178–182.
3. Brahams D. Perforation of heart during attempt to drain pleural cavity. *Lancet* 1986; 8506:586.
4. Meisel S, Ram Z, Priel I, et al. Another complication of thoracostomy-perforation of the right atrium. *Chest* 1990; 98:772–773.
5. Shih CT, Chang Y, Lai ST. Successful management of perforating injury of right atrium by chest tube. *Zhonghua Yi Xue Za Zhi (Taipei)* 1992; 50:338–340.
6. Domínguez Fernández E, Neudeck F, Piotrowski J. Perforation of the heart wall—a rare complication after thoracic drainage treatment. *Chirurg* 1995; 66:920–922.
7. Kopec SE, Conlan AA, Irwin RS. Perforation of the right ventricle: a complication of blind placement of a chest tube into the postpneumectomy space. *Chest* 1998; 114:1213–1215.
8. Abad C, Padrón A. Accidental perforation of the left ventricle with a chest drain tube. *Tex Heart Inst J* 2002; 29:143.
9. Laws D, Neville E, Duffy J; Pleural Diseases Group, Standards of Care Committee, British Thoracic Society. BTS guidelines for the insertion of a chest drain. *Thorax* 2003; 58 Suppl 2:ii53–59.
10. Akhan O, Ozkan O, Akinçi D, et al. Image-guided catheter drainage of infected pleural effusions. *Diagn Interv Radiol* 2007; 13:204–209.